

A Prospective, Multicenter, Randomized-Controlled 5-Year Study of Hybrid and Fully Etched Implants for the Incidence of Peri-Implantitis

Lars Zetterqvist,* Sylvan Feldman,†† Bruce Rotter,§ Giampaolo Vincenzi,|| Jan L. Wennström,¶ Andrea Chierico,|| Renée M. Stach,# and James N. Kenealy#

Background: The dual acid-etched (DAE) implant was commercially introduced in 1996 with a hybrid design incorporating a machined surface in the coronal region from approximately the third thread to the seating surface. This design was intended to reduce the risks of peri-implantitis and other related soft tissue complications that were reported for implants with surface roughness in the coronal region. The objective of this prospective, randomized-controlled clinical trial was to determine the incidence of peri-implantitis for a fully etched implant with the DAE surface extending to the implant platform.

Methods: Patients had implant sites randomly assigned to receive one hybrid control implant and at least one fully etched test implant in support of a short-span fixed restoration to ensure that variables (e.g., demographics, jaw locations, and bone density) were consistent between groups. Prostheses were inserted 2 months after implant placement with follow-up evaluations scheduled annually for 5 years to assess mucosal health based on bleeding on probing, suppuration, and probing depths. Evaluations also included radiographic and mobility assessments.

Results: One hundred twelve patients who were enrolled at seven centers received 139 control and 165 test implants (total: 304 implants). With >5 years of postloading evaluations, there was one declaration of peri-implantitis associated with a control implant that was successfully treated later. Clinical probing and radiographic assessments did not reveal differences between groups in mucosal health outcomes or other signs of peri-implantitis.

Conclusion: Five-year results of this randomized-controlled study showed no increased risk of peri-implantitis for fully etched implants compared to hybrid-designed implants. *J Periodontol* 2010;81:493-501.

KEY WORDS

Alveolar bone loss; biofilms; dental implants; mucositis; randomized-controlled trial.

The dual acid-etched (DAE)** implant introduced in 1996 incorporates a hybrid design with a machined surface extending from approximately the third thread to the seating surface. The selection of this design was made to avoid the risks of mucosal complications that were reported for other implants with roughened surfaces in the coronal area, particularly hydroxyapatite (HA) and titanium plasma spray (TPS) surfaces.¹ Contemporaneous observations of catastrophic implant failures with HA-, TPS-, and fully etched-designed implants led to a suspicion that a rough surface near the seating platform contributed to mucosal complications and adverse events.²⁻⁶ Because a smooth, machined surface in the coronal region is more readily debrided of biofilm,⁷ it was assumed that a hybrid design would better ensure mucosal health and lower the risk of peri-implant diseases surrounding osseointegrated implants. When bacterial plaque accumulates, especially in patients with poor oral hygiene, biofilm harbors microbes that can cause a reversible inflammatory reaction, termed “mucositis,” in peri-implant soft tissues; this can subsequently lead to “peri-implantitis,” a progressive, chronic, inflammatory infection

* Private practice, Gefle, Sweden.

† Private practice, Towson, MD.

†† Department of Periodontology, University of Maryland, Baltimore, MD.

§ Department of Oral Surgery, Southern Illinois University, Edwardsville, IL.

|| Private practice, Verona, Italy.

¶ Department of Periodontology, Gothenburg University, Gothenburg, Sweden.

Clinical Research Department, Biomet 3i, Palm Beach Gardens, FL.

** Osseotite, Biomet 3i, Palm Beach Gardens, FL.

of the soft tissues with subsequent irreversible bone loss.⁸ Both mucositis and peri-implantitis were observed as contributing to failures of implants with HA-coated surfaces.⁹

With all two-stage implant systems, there is regressive crestal bone remodeling after the placement of a transmucosal abutment. This observed bone loss is considered acceptable according to the success criteria proposed by Albrektsson et al.¹⁰ and Smith and Zarb.¹¹ Nevertheless, crestal bone regression could possibly lead to exposure of the DAE surface. This concern was instrumental in finalizing the hybrid design with the machined surface featured down to the third thread. Therefore, the DAE implant was initially commercially released with the hybrid design.

Since the introduction of the DAE-surfaced implant, prospective, multicenter clinical studies reported 3- to 6-year cumulative survival rates (CSRs) ranging up to 99.3%.¹²⁻¹⁷ Meta-analysis of published data shows no decrease in performance for DAE-surfaced implants under conditions considered to be a high risk for implant failure, e.g., in poor bone quality,¹⁸ in poor bone quantity,¹⁹ or in patients who smoke.²⁰ Furthermore, human histologic and histomorphometric evaluations show significantly greater bone-implant contact at the DAE surface compared to the machined surface.²¹⁻²³

Because of the recognition of the benefits of the DAE surface, the hypothesized but unsubstantiated safety contributions of the hybrid design may be challenged and clinician interest in extending the DAE surface to the seating platform has emerged. With the hybrid design, the machined surface is positioned at the cortical portion of bone where initial implant fixation is most critical. Also, users of short implants (<10 mm) noted that the hybrid design leaves about half of the implant with a machined surface, which could pose an increased risk for failure in sites with poor quality bone.^{18,19} The potential benefits of having the DAE surface complexity on all implant surfaces with osseous contact have to be considered against the possibility of increasing the incidence of peri-implantitis. Clinician interest in a fully DAE-surfaced implant led to a specific effort to quantify the risk of adverse events for fully etched implants. Therefore, this prospective, randomized-controlled clinical trial is designed to determine whether a difference exists in the incidence of peri-implantitis between hybrid and fully etched implants.

MATERIALS AND METHODS

Study Implants

All implants evaluated in this clinical trial had a surface complexity generated by a dual acid-etching process.^{††} Control implants were those with a hybrid design where the DAE surface includes all areas from the apex to the top of the third coronal thread. A ma-

chined surface continued from this point up to the seating platform (Fig. 1A). Test implants had a continuous DAE surface from the apex to the seating platform (Fig. 1B). Other than the regions of surface complexity, the overall physical design of the test and control implants used in the study was identical. All study implants were composed of commercially pure titanium and had an external hexed-abutment fixation mechanism and a self-tapping apex. Implant dimensions available for the study were limited to diameters of 3.75 and 4 mm and lengths ranging from 8.5 to 18 mm. Restorative components used in the study are all commercially available and provided by the manufacturer.^{‡‡}

Profilometric analysis, using a scanning electron microscope,^{§§} was performed to create surface maps and to quantify the surface roughness of applicable implant surfaces. High-resolution, three-dimensional scans at a magnification $\times 1,000$ were conducted on two representative test and two representative control implants. The regions assessed included the DAE surface and machined collar of control implants and the DAE surface of test implants. Five scans were carried out per implant on the respective regions, providing 10 total scans for each respective surface.

All scans were post-processed using software.^{|||} The post-processing included a 50×50 -micron Gaussian filtration and an inverse fast fourier transform. The fourier analysis, which separates low- and high-frequency data, was used to quantify the contributions of roughness elements of the surface from the coarser waviness elements generally imparted by the overall surface curvature. Surface-mapping data were analyzed using the Fisher protected least significant difference method.^{¶¶}

Patient Selection

Study inclusion criteria consisted of patients >18 years of age for whom a decision had already been made to use implants for the treatment of a partial posterior edentulism and who were physically able to tolerate conventional surgical and restorative procedures. Exclusion criteria consisted of evidence of active infection or severe inflammation in areas intended for implant placement, a smoking habit of ≥ 10 cigarettes per day as reported on a screening questionnaire, uncontrolled diabetes, metabolic bone disease, therapeutic radiation to the head within the past 12 months, evidence of severe parafunctional habits, and pregnancy.

†† Osseotite, Biomet 3i.

‡‡ Biomet 3i.

§§ ADE Phase Shift MicroXAM100 Optical Interferometric Surface Profiler, ADE Phase Shift, Tucson, AZ.

||| ADE Phase Shift MapVue AE, ADE Phase Shift.

¶¶ StatView v5.0.1, SAS Institute, Cary, NC.




Figure 1.

A) The control implant: hybrid design. **B)** The test implant: fully etched. Implants are made of commercially pure titanium with straight walls, apical cutting features, and external hex connections. In this figure, implant dimensions are 4 × 8.5 mm.

Patients who met the admission criteria and provided written informed consent were assigned a unique study identification number to which prospective implant sites would be randomly assigned to either the test or control groups. Study restorations were to be two-, three-, or four-unit fixed prostheses to ensure that conditions for both test and control implants were as similar as possible. A statistician generated a randomization scheme for the project. Randomization cards were provided to investigators (LZ, SF, BR, GV, JLW, and AC) for each case and had tamper-evident masking. Each card included a treatment-allocation scheme allowing for two, three, or four implant sites. These were unmasked during surgery at the time of implant placement. Requirements for implant placement included ≥ 1 mm of bone available at the buccal and lingual aspects of the implant and ≥ 1 mm of bone below the apex. Anatomic requirements for prosthetic fabrication included an alveolar ridge width ≥ 6 mm and a bone height ≥ 5 mm above the mandibular canal.

Surgical Procedures

Surgical calibration of the investigators included previous experience with the implant system and the use of identical surgical kits, drills, and handpieces provided by the manufacturer.^{##} The drilling sequence and implant-placement protocol included specific instructions described in the manufacturer's surgical manual. Implants were to be placed without counter-sink drilling, leaving the implant seating surface 0.7

mm above the alveolar bone. All implants were to be placed in an open surgical field with full mucoperiosteal flaps in a single-stage surgical approach with the placement of a healing abutment prior to repositioning the mucosa. After 6 weeks of healing, impressions were taken to fashion provisional restorations that were inserted at 8 weeks. The final prostheses were delivered within 6 months.

Evaluation Criteria

At the restorative visit and each follow-up visit (annually for 5 years), patients were interviewed for any subjective symptoms of pain or paresthesia that might indicate infection. The modified sulcus bleeding index (SBI)²⁴ was used to assess the bleeding tendency of the marginal peri-implant tissues at the mesial, distal, buccal, and lingual aspects of each implant. Probing depths measured at the mesial, distal, buccal, and lingual surfaces were recorded to the nearest half millimeter. In addition, suppuration was reported as either a yes or no during the probing procedure. Measures of overall oral hygiene conditions were recorded at each evaluation by the use of the plaque index²⁵ and gingival index.²⁶ If any signs or symptoms of implant mobility were present, the prosthesis was removed to allow an implant mobility assessment. Mobility testing was performed by removing the prosthesis, attaching a post, and an opposing force from two hand instruments (e.g., mirrors) was applied.

Radiographic Analyses

Periapical radiographs of all study implant sites and any proximal edentulous areas were obtained and inspected to detect signs of peri-implant radiolucencies at the 2-month provisionalization visit (baseline), at 6 months (permanent prosthesis attachment), and, thereafter, annually for 5 years after prosthesis insertion. Periapical radiographs were taken with the patient wearing a customized plastic bite block^{***} filled with acrylic resin to ensure that a parallel technique was replicated at each study interval.

Individual study radiographs were inspected to identify progressive bone loss. For the measurement of crestal bone regressive modeling, qualified radiographs with sufficient resolution, clarity, and content were included in the analyses. Radiographic films were scanned by a flatbed scanner with a transparency module,^{†††} and images were saved as high-resolution files. Crestal bone landmarks on each radiographic image were marked by one clinician evaluator (Dr. Richard Caudill, private practice, Tequesta, FL). On both the mesial and distal aspects of the implant, the evaluator scored two marks designating where the crestal bone intersected the implant body apically

^{##} Biomet 3i.

^{***} Rinn, Dentsply Rinn, Elgin, IL.

^{†††} UMAX PowerLook 2100XL, Umax Technologies, Techville, Dallas, TX.

and coronally. A reference line was placed across the implant–abutment interface. Bone-height measurements were made using software.^{†††} A calibration step was performed using known implant dimensions (implant length or collar width) and the observed implant dimensions to normalize and compensate for possible angulation and proximity effects. The distance between the crestal bone–implant intersection point and the reference line was used to score the crestal bone height. Distances were measured to the nearest 0.01 mm. Significance testing was done using analysis of variance.

Reporting of Peri-Implantitis

Requirements for a declaration of peri-implantitis included all three of the following: mucositis with a positive finding of bleeding and/or suppuration upon probing; a probing depth >5 mm; and crestal bone loss that was progressive, >5 mm, and confirmed by radiography. The determination of significance of outcomes from the two implant groups for the incidence of peri-implantitis was performed using χ^2 analysis.

RESULTS

Surface mapping microscopy images are presented in Figure 2 and include representative samples of surfaces on both implant types illustrating the similarities of the DAE regions on the control and test implants and the differences to the machined surface on the control implant. Sa values for the DAE surface were 0.411 μm on control implants and 0.436 μm on test implants ($P > 0.05$). The Sa value was 0.178 μm for the machined surface on the control implants and was significantly different from the Sa value for the DAE surface ($P < 0.05$).

Prior to the initiation of patient enrollment, the study centers obtained review committee approval. Between September 2000 and June 2002, 112 patients (age range: 22.6 to 80.3 years; mean age: 59.1 ± 8.2 years) were enrolled at seven centers within Europe (at Gothenburg University, Gothenburg, Sweden; Gefle, Sweden; and Verona, Italy) and the United States (at Southern Illinois University, Edwardsville, Illinois; the University of Florida, Gainesville, Florida; and Towson, Maryland). Descriptive statistics for the patient population included gender, smoking status, and relevant medical conditions. At the time of enrollment, the statistics were as follows: 46% (50) of subjects were male with a mean age of 59.3 years, and 54% (56) of subjects were female with a mean age of 58.9 years; of the female patients, 44% were postmenopausal. Fifteen percent of all patients were smokers as reported on screening forms.

A total of 304 implants were placed supporting 127 prostheses with a distribution of 139 control and 165

test implants in 112 patients. The distribution of control and test implants by tooth numbers in maxillae and mandibles is depicted in Figure 3. Both groups had implants placed predominantly in the mandible. The results of clinical assessments of bone quality at placement surgery²⁷ for all implants were as follows: 11.0% in dense bone, 67.4% in normal bone, and 21.6% in soft bone. Regarding implant dimensions, 60% were 4 mm in diameter, and 40% were 3.75 mm in diameter. The distributions of implants by length were as follows: 35% were ≤ 10 mm, 33% were 11.5 mm, 22% were 13 mm, and 10% were ≥ 15 mm.

During 5 years of observations, a total of 16 patients (14.2%) did not return for annual evaluations, and these cases were designated as lost to follow-up. The data collected at each follow-up assessment from mucosal probing at the mesial, distal, buccal, and lingual aspects of each implant for the detection of bleeding (SBI) and probing depth measurements are presented in Table 2. The probing data show that results for control and test groups were similar throughout the study. More than 83% of all SBI scores for implants in either group, throughout the 5 years of follow-up, were 0, and for $\leq 0.3\%$ of implants in either group, the score was 3. The probing depth values reported in Table 2 are the increased changes from the baseline values obtained at the prosthesis insertion visit 6 months after implant placement surgery. For both implant groups, the majority of values were within the 0- to 1-mm range, and no values were ≥ 3 mm.

During the course of the study, one case of peri-implantitis was reported for an overall incidence of 0.37%, and no statistical difference was observed between implant groups ($P > 0.05$). The one peri-implantitis case occurred in a patient previously treated for advanced chronic periodontitis. At the patient's 3-year annual follow-up evaluation, a control implant (hybrid design) placed in the posterior maxilla presented with a 6-mm probing depth, bleeding on probing, and radiographic bone loss. This implant was part of a two-unit fixed prosthesis, and the other implant (test) included in the case showed no clinical signs of pathology. After surgical intervention for debridement of the affected implant, clinically healthy conditions with probing depths ≤ 4 mm were reestablished. However, at the final 5-year annual follow-up evaluation, a recurrence of pathology (bleeding and suppuration) was observed. Despite non-surgical subgingival debridement of the implant, signs of pathology remained, and therefore, surgical debridement combined with systemic antibiotic therapy (doxycycline, 100 mg, daily for 7 days) was performed. Three months later, the implant showed

††† UTHSCSA ImageTool (IT), v3.0, University of Texas Health Science Center, San Antonio, TX.

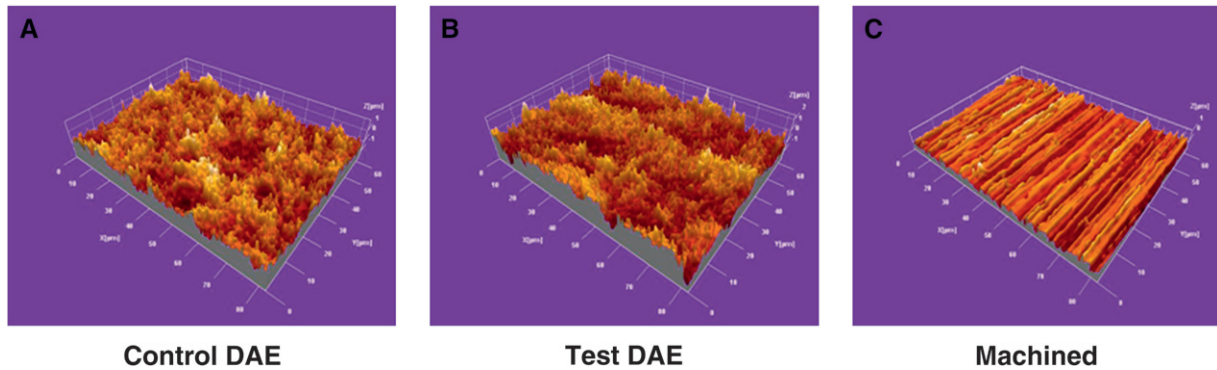


Figure 2. Topographies of the DAE surfaces on control (A) and test (B) implants were qualitatively similar to each other and different than the topography of the machined surface (C) as represented in surface-mapping microscopy images.

Table 1.
Surface-Map Analysis for DAE and Machined Surfaces

	Sa (μm)			Sq (μm)			PV (μm)		
	A (control DAE)	B (test DAE)	C (machined)	A (control DAE)	B (test DAE)	C (machined)	A (control DAE)	B (test DAE)	C (machined)
Mean	0.411	0.436	0.178	0.516	0.552	0.225	4.121	4.479	1.680
SD	0.039	0.036	0.009	0.052	0.052	0.009	0.445	0.711	0.126

Sa = arithmetic mean of the departures of the roughness area of the mean plane; Sq = root mean square variation over the surface; PV = highest peak to lowest valley.

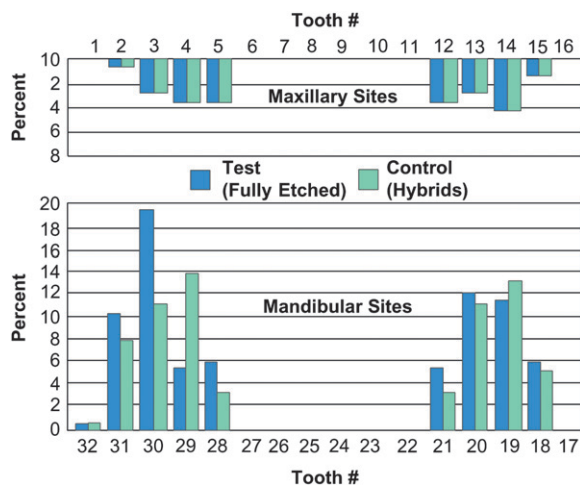


Figure 3. The distribution (%) of control (hybrid design) and test (fully etched) implants by tooth site numbers (according to the Universal/National System) in the maxilla and mandible.

shallow probing depths (≤ 4 mm) and no bleeding or suppuration.

Other than this case, there was only one other positive score for suppuration for one control implant, which was observed at the baseline evaluation but

was not detected at the subsequent evaluation. One incidence of radiolucency was reported, which was detected on a baseline radiograph, for one control implant, and on the subsequent 6-month radiograph, the radiolucency was no longer observed. Measurements of general oral health and hygiene, as reported using the gingival and plaque indices, revealed a slight upward trend during the course of the study (Fig. 4).

The analysis of qualified study implant radiographs showed a difference between implant groups in crestal bone regressive-modeling outcomes as illustrated in Figure 5. The number of implants in this illustration represents radiographs qualified for this analysis at each study interval, whereas all radiographs for all patients were inspected for progressive bone loss. A similar extent of bone regression was observed for both implant types in the first 6 months from provisionalization. Thereafter, crestal bone levels were self-limiting and never exceeded a mean change from baseline of 1.2 mm. The loss of crestal bone was less for the fully etched group compared to the hybrid implants, and this difference was statistically significant at the $P < 0.0001$ level. Throughout the 5 years of monitoring, no crestal bone loss exceeded 5.0 mm for all but the one implant associated with peri-implantitis.

Table 2.
SBI Scores and Probing Depth Intervals for Control and Test Implant Groups

	Control (%)	Test (%)	Control (n)	Test (n)
SBI* Scores				
0	83.5	84.3	–	–
1	13.6	13.1	–	–
2	2.6	2.4	–	–
3	0.3	0.2	–	–
PD intervals [†] (changes from BL [mm])				
0 to 1	–	–	147	119
1.5 to 3	–	–	36	35
3.5 to 5	–	–	0	0
≥5	–	–	0	0

– = not applicable; BL = baseline; n = numbers of sites where there was a finding of increased probing depth corresponding to intervals.

* 0 = no bleeding; 1 = an isolated bleeding spot was visible; 2 = blood formed a confluent red line on the mucosal margin; and 3 = heavy or profuse bleeding.

† Probing depth intervals (millimeters) are changes from baseline (BL) to the 6-month permanent prosthesis insertion.

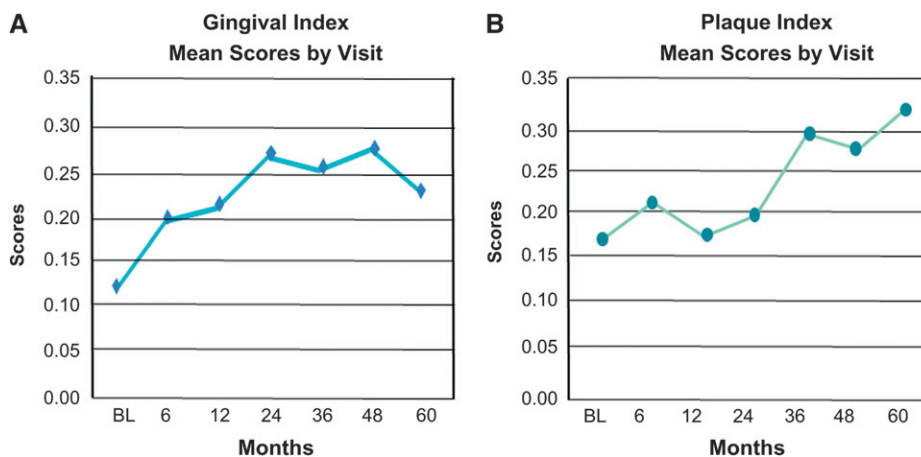


Figure 4.

A) Mean scores for the gingival and plaque indices through 60 months of follow-up assessments are <1.0. Gingival index scores: 0 = absence of inflammation; 1 = mild inflammation, slight change in color, and little change in texture; and 2 = moderate inflammation, moderate glazing, redness, edema hypertrophy, and bleeding on probing; (3) = severe inflammation, marked redness and hypertrophy, tendency to spontaneously bleed, ulceration. **B)** Plaque index scores: 0 = no plaque; 1 = plaque was not visible to the unaided eye, but when the tip of a probe was run across the gingival margin, a thin film of plaque was seen; 2 = moderate accumulation of soft deposits at the gingival margin and/or on the tooth surface visible to the naked eye; and 3 = abundance of soft matter at the gingival margin, in the gingival pocket, and on the surface of the tooth. BL = baseline (implant placement).

DISCUSSION

Since the introduction of root-form dental implants in the 1970s, changes in implant design have led to considerable improvements in overall success rates. A specific example is the addition of surface complexity to the machined-surface threaded implant. The profilometry data determined for the DAE surface on control and test implants in this study fall within the range

of profilometry values reported by the manufacturer for the DAE surface on commercially pure titanium.²⁸ Profilometry values for the DAE surface are at least twice those for the machined-surface portions on the hybrid implant.

Solely on the basis of increased surface complexity, CSRs increased significantly for implants with DAE surfaces.¹²⁻¹⁷ Mechanisms by which the increased surface roughness contributes to the substantive improvements in clinical performance were proposed. Park and Davies²⁹ showed that, compared to a machined surface, the platelet adhesion and activation on the DAE surface may contribute to the acceleration of osseogenesis immediately upon implant placement into blood within the osteotomy. Davies³⁰ recognized that the DAE surface is osteoconductive, allowing fibrin to attach and osseogenic cells to migrate along a connective tissue scaffold toward the implant surface and to secrete *de novo* bone directly onto the implant surface. At the molecular level, the topography of the DAE surface was shown to modulate extracellular gene expression of osteonectin and osteocalcin, both having an effect on bone-implant integration.³¹

For implants with a roughened coronal surface, a biofilm of bacteria forms in and around the implant upon exposure to the oral environ-

ment.³² Because these microorganisms may persist and proliferate, they are a leading contributor to peri-implantitis, which can lead to the loss of implant integration.³³ A large proportion of the partially edentulous population receiving implant treatment includes patients who lost teeth due to tissue destruction and periodontitis.³⁴ In patients with periodontal disease, it was shown that bacteria can be

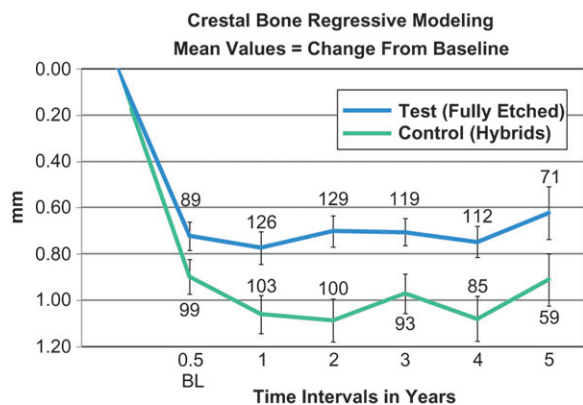


Figure 5.

Crestal bone values were mean changes measured from baseline in millimeters through 5 years of evaluations for control (hybrid design) and test (fully etched) implant groups. BL = baseline (provisionalization); error bars = SE values. Values at error bars indicate the number of implants evaluated at that interval.

transmitted from periodontal pockets in other regions of the mouth to the peri-implant region and that periodontitis is a risk factor for peri-implantitis.³⁵ Another risk factor associated with peri-implantitis is tobacco use, as demonstrated in a large retrospective study.³⁶ Recent research^{37,38} focused on identifying an association between genetic markers and peri-implantitis. However, there is not enough evidence to support the diagnostic value of genetic susceptibility tests to assess a patient's risk for peri-implantitis.^{37,38} It is recommended that all potential risk factors that might predispose an implant to inflammatory reactions should be recognized when considering the etiology of peri-implantitis.

Peri-implantitis can be difficult to treat with local and systemic antimicrobial approaches,³⁹ and even with surgical interventions.^{40,41} Because the accumulation of biofilm can be responsible for the introduction of bacteria at the mucosal margin of the implant, the role of oral hygiene is considered critical for prevention. Prevailing treatment modalities include conservative approaches such as adjunctive local antimicrobial rinses, e.g., chlorhexidine, in combination with a patient's daily use of a soft toothbrush to combat the inflammatory response.⁴² Non-surgical mechanical debridement can be performed with hand instruments or ultrasonic devices with no discernible differences in the resolution of outcomes.⁴³ Surgical tissue flap exposure, often the next treatment modality, allows access to the implant threads for mechanical debridement and rinsing with solutions such as citric acid or hydrogen peroxide. Ultimately, bone augmentation with or without a bioabsorbable membrane may be required to salvage the implant.⁴⁴ The failure to detect signs of mucositis and peri-implantitis and to initiate proper intervention can lead to progressive bone

loss resulting in implant failure. In the present study, the one peri-implantitis case was successfully treated with surgical debridement and systemic antibiotics.

When signs of peri-implantitis are observed in the early stages, current treatments can be reasonably successful,^{45,46} and the possibility for bone regeneration is higher for implants that previously may have been unsalvageable. The early clinical detection of mucositis and peri-implantitis is best accomplished with systematic mucosal probing techniques to measure the probing depth and to reveal bleeding on probing and the presence of suppuration.⁴⁵ Historically, there is a perception that probing around implants should be avoided.⁴⁷ Probing alone is not a purely diagnostic test for peri-implantitis, but it is a more efficient and effective technique than other methods, such as the commercially available tests used to detect bacterial strains in crevicular fluid. In this study, clinical observations of mucosal health based on the probing methods indicate a low incidence of any possible sign of peri-implantitis based on the results from the SBI scores: for both groups, 83% were ranked 0, and one site throughout the course of the study scored positive for suppuration.

According to Mombelli,⁴⁶ a loss of crestal bone beyond stabilized regressive remodeling, in conjunction with probing depths ≥ 5 mm, is necessary for a differential diagnosis of peri-implantitis. In the present study, radiographic evidence of bone loss was initially obtained at provisionalization and again at each annual follow-up appointment. The pattern of regression was notable for its self-limiting profile with no progressive regression observed in the mean values after the insertion of the permanent prosthesis 6 months after implant placement. These data demonstrate a compliance with the success criteria of Albrektsson et al.⁸ The difference in the extent of regression between the hybrid and fully etched versions of the implant suggest some mechanism or capacity of the DAE surface to resist the forces that cause bone regression. Baseline radiographs were obtained at provisionalization after 2 months of healing with transmucosal abutments. During this time, additional crestal bone regression took place but was not captured in the study.

There is limited information on the incidence of peri-implantitis in the literature because there are few studies that report observations that adhere to a conventional definition of peri-implantitis.⁴⁸ Estimates range from 0% to 14.4%,⁴⁹ and the frequency of the disease may increase as a result of increasing years of implant function.⁴⁶ Nonetheless, it is a clinical reality, and the stigma of this condition is an ever-present concern, especially for users of implants with HA and TPS coatings. However, the failure rates reported for HA implants, initially attributed to surface roughness and peri-implantitis, were possibly caused

by a different mechanism. Because the extent of crystallinity of plasma-sprayed HA coatings can affect stability in vivo,⁵⁰ such amorphous, unstable coatings do not biodegrade or integrate homogeneously, and large fragments can disintegrate and lead to implant failure.⁵¹ Reportedly, all commercial HA coatings are susceptible to dissolution.⁵² The observations of failures were eventually understood to have been caused by a delamination of the HA coating. In contrast, for the DAE-surfaced implants, acids are used in a reductive approach. As a result, there is no coating, and DAE implants are not subject to a delamination failure mode.

The main objective of this study is to determine the clinical safety and efficacy for implants with the DAE surface at the mucosal interface after 5 years of observation; this objective was achieved. Because peri-implantitis has a late onset, tissue destruction may not be detected until observation periods ≥ 5 years. Control and test implant types were placed in each patient in support of the same restoration to ensure that differences in location, bone density, and oral hygiene did not affect outcomes. Results from mucosal probing evaluations to detect bleeding and suppuration were consistent between the groups. With only one report of peri-implantitis observed in this study, the power to make a definitive assessment of safety for the fully etched version of the implants was limited by the sample size because the study was originally powered to detect a higher incidence of peri-implantitis. With no clinical or radiographic signs of peri-implantitis for the fully etched surfaced implants, there was no evidence of an increased risk.

CONCLUSIONS

The results of this study suggest that an implant designed with a DAE surface extending from the apex to the abutment seating platform does not adversely affect mucosal health or increase the risk of peri-implantitis. The presence of the roughened surface at the collar is of interest for its effect of preserving crestal bone, which is essential for maintaining soft tissue stability and esthetics.

ACKNOWLEDGMENTS

The authors thank Dr. Richard Caudill, periodontist, private practice, Tequesta, Florida, for radiographic analysis, and Dr. Prabhu Gubbi, Senior Materials Scientist, Biomet 3i, Palm Beach Gardens, Florida, for performing microscopy and providing profilometry surface-map data analysis. Dr. Stach is Senior Medical Writer, Clinical Research Department at Biomet 3i, and Dr. Kenealy is the Director of the Clinical Research Department at Biomet 3i. Biomet 3i provided financial support, materials, and equipment for the study.

REFERENCES

1. Bollen CM, Papaioanno W, Van Eldere J, Schepers E, Quirynen M, van Steenberghe D. The influence of abutment surface roughness on plaque accumulation and peri-implant mucositis. *Clin Oral Implants Res* 1996;7:201-211.
2. Block MS, Gardiner D, Kent JN, Misiek DJ, Finger IM, Guerra L. Hydroxyapatite-coated cylindrical implants in the posterior mandible: 10-year observations. *Int J Oral Maxillofac Implants* 1996;11:626-633.
3. Cosci F, Cosci B. A 7-year retrospective study of 423 immediate implants. *Compend Contin Educ Dent* 1987;18:940-942, 944, 946 passim.
4. Hanisch O, Cortella CA, Boskovic MM, James RA, Slots J, Wikesjö UM. Experimental peri-implant tissue breakdown around hydroxyapatite-coated implants. *J Periodontol* 1997;68:59-66.
5. Piattelli A, Cosci F, Scarano A, Trisi P. Localized chronic suppurative bone infection as a sequel of peri-implantitis in a hydroxyapatite-coated dental implant. *Biomaterials* 1995;16:917-920.
6. Wang IC, Reddy MS, Geurs NC, Jeffcoat MK. Risk factors in dental implant failure. *J Long Term Eff Med Implants* 1996;6:103-117.
7. Pontoriero R, Tonelli MP, Carnevale G, Mombelli A, Nyman SR, Lang NP. Experimentally induced peri-implant mucositis. a clinical study in humans. *Clin Oral Implants Res* 1994;5:254-259.
8. Mombelli A, Lang NP. The diagnosis and treatment of peri-implantitis. *Periodontol 2000* 1998;17:63-76.
9. Albrektsson T, Wennerberg A. Oral implant surfaces: Part 1—review focusing on topographic and chemical properties of different surfaces and in vivo responses to them. *Int J Prosthodont* 2004;17:536-543.
10. Albrektsson T, Zarb GA, Worthington P, Eriksson AR. The long-term efficacy of currently used dental implants: A review and proposed criteria for success. *Int J Oral Maxillofac Implants* 1986;1:11-25.
11. Smith DE, Zarb GA. Criteria for success of osseointegrated endosseous implants. *J Prosthet Dent* 1989;62:567-572.
12. Gaucher H, Bentley K, Roy S, et al. A multi-centre study of Osseotite implants supporting mandibular restorations: A 3-year report. *J Can Dent Assoc* 2001;67:528-533.
13. Grunder U, Gaberthuel T, Boitel N, et al. Evaluating the clinical performance of the Osseotite implant in maxillary and mandibular posterior areas: Defining prosthetic predictability. *Compend Contin Educ Dent* 1999;20:628-640.
14. Khang W, Feldman S, Hawley CE, Gunsolley J. A multi-center study comparing dual acid-etched and machined-surfaced implants in various bone qualities. *J Periodontol* 2001;72:1384-1390.
15. Mayer TM, Hawley CE, Gunsolley JC, Feldman S. The single-tooth implant: A viable alternative for single tooth replacement. *J Periodontol* 2002;73:687-693.
16. Sullivan DY, Sherwood RL, Porter SS. Long term performance of Osseotite implants: A 6-year clinical follow-up. *Compend Contin Educ Dent* 2001;22:326-328, 330, 332-334.
17. Testori T, Wiseman L, Woolfe S, Porter SS. A prospective multicenter clinical study of the Osseotite implant: Four-year interim report. *Int J Oral Maxillofac Implants* 2001;16:193-200.
18. Stach RM, Kohles SS. A meta-analysis examining the clinical survivability of machined-surfaced and

- Osseotite implants in poor quality bone. *Implant Dent* 2003;12:87-96.
19. Feldman S, Boitel N, Weng D, Kohles SS, Stach RM. Five-year survival distributions of short-length (10 mm or less) machined-surfaced and Osseotite implants. *Clin Implant Dent Relat Res* 2004;6:16-23.
 20. Bain CA, Weng D, Meltzer A, Kohles SS, Stach RM. A meta-analysis evaluating the risk for implant failure in patients who smoke. *Compend Contin Educ Dent* 2002;23:695-699, 702, 704 passim; quiz 708.
 21. Lazzara RJ, Testori T, Trisi P, Porter SS, Weinstein RL. A human histologic analysis of Osseotite and machined surfaces using implants with 2 opposing surfaces. *Int J Periodontics Restorative Dent* 1999;19:117-129.
 22. Trisi P, Lazzara R, Rao W, Rebaudi A. Bone-implant contact and bone quality: Evaluation of expected and actual bone contact on machined and Osseotite implant surfaces. *Int J Periodontics Restorative Dent* 2002;22:535-545.
 23. Trisi P, Lazzara R, Rebaudi A, Rao W, Testori T, Porter SS. Bone-implant contact on machined and Osseotite surfaces after 2 months of healing in the human maxilla. *J Periodontol* 2003;74:945-956.
 24. Mombelli A, van Oosten MA, Schurch E Jr., Land NP. The microbiota associated with successful or failing osseointegrated titanium implants. *Oral Microbiol Immunol* 1987;2:145-151.
 25. Silness J, Løe H. Periodontal disease in pregnancy. II. Correlation between oral hygiene and periodontal condition. *Acta Odontol Scand* 1964;22:121-135.
 26. Løe H, Silness J. Periodontal disease in pregnancy. I. Prevalence and severity. *Acta Odontol Scand* 1963;21:533-551.
 27. Trisi P, Rao W. Bone classification: Clinical-histomorphometric comparison. *Clin Oral Implants Res* 1999;10:1-7.
 28. Gubbi P, Berckmans B. Characterization of Osseotite surfaces on cp titanium and titanium alloy dental implants. In: Kotula P, Marko M, Scott J-H, et al., eds. *Proceedings Microscopy and Microanalysis*. Cambridge: Cambridge University Press; 2006:122-123.
 29. Park JY, Davies JE. Red blood cell and platelet interactions with titanium implant surfaces. *Clin Oral Implants Res* 2000;11:530-539.
 30. Davies JE. Mechanisms of endosseous integration. *Int J Prosthodont* 1998;11:391-401.
 31. Ogawa T, Nishimura I. Different bone integration profiles of turned and acid-etched implants associated with modulated expression of extracellular matrix genes. *Int J Oral Maxillofac Implants* 2003;18:200-210.
 32. Berglundh T, Gislason O, Lekholm U, Sennerby L, Lindhe J. Histopathological observations of human peri-implantitis lesions. *J Clin Periodontol* 2004;31:341-347.
 33. Mombelli A. Etiology, diagnosis, and treatment considerations in peri-implantitis. *Curr Opin Periodontol* 1997;4:127-136.
 34. Hultin M, Gustafsson A, Hallström H, Johansson LA, Ekfeldt A, Klinge B. Microbiological findings and host response in patients with peri-implantitis. *Clin Oral Implants Res* 2002;13:349-358.
 35. Sumida S, Ishihara K, Kishi M, Okuda K. Transmission of periodontal disease-associated bacteria from teeth to osseointegrated implant regions. *Int J Oral Maxillofac Implants* 2002;17:696-702.
 36. Haas R, Haimböck W, Mailath G, Watzek G. The relationship of smoking on peri-implant tissue: A retrospective study. *J Prosthet Dent* 1996;76:592-596.
 37. Andreiotelli M, Koutayas SO, Madianos PN, Strub JR. Relationship between interleukin-1 genotype and peri-implantitis: A literature review. *Quintessence Int* 2008;39:289-298.
 38. Huynh-Ba G, Lang NP, Tonetti MS, Zwahlen M, Salvi GE. Association of the composite IL-1 genotype with peri-implantitis: A systematic review. *Clin Oral Implants Res* 2008;19:1154-1162.
 39. Bach G, Neckel C, Krekeler G. Conventional versus laser-assisted therapy of periimplantitis: A five-year comparative study. *Implant Dent* 2000;9:247-251.
 40. Schwarz F, Sculean A, Bieling K, Ferrari D, Rothamel D, Becker J. Two-year clinical results following treatment of peri-implantitis lesions using a nanocrystalline hydroxyapatite or a natural bone mineral in combination with a collagen membrane. *J Clin Periodontol* 2008;35:80-87.
 41. Claffey N, Clarke E, Polyzois I, Renvert S. Surgical treatment of peri-implantitis. *J Clin Periodontol* 2008;35(8 Suppl.):316-332.
 42. Salvi GE, Persson GR, Heitz-Mayfield LJ, Frei M, Lang NP. Adjunctive local antibiotic therapy in the treatment of peri-implantitis II: Clinical and radiographic outcomes. *Clin Oral Implants Res* 2007;18:281-285.
 43. Renvert S, Samuelsson E, Lindahl C, Persson GR. Mechanical non-surgical treatment of peri-implantitis: A double-blind randomized longitudinal clinical study. I: Clinical results. *J Clin Periodontol* 2009;36:604-609. (erratum 2009;36:1076).
 44. Roos-Jansäker AM, Renvert H, Lindahl C, Renvert S. Surgical treatment of peri-implantitis using a bone substitute with or without a resorbable membrane: A prospective cohort study. *J Clin Periodontol* 2007;34:625-632.
 45. Lang NP, Berglundh T, Heitz-Mayfield LJ, Pjetursson BE, Salvi GE, Sanz M. Consensus statements and recommended clinical procedures regarding implant survival and complications. *Int J Oral Maxillofac Implants* 2004;19(Suppl.):150-154.
 46. Mombelli A. Microbiology and antimicrobial therapy of peri-implantitis. *Periodontol* 2000 2002;28:177-189.
 47. Klinge B, Hultin M, Berglundh T. Peri-implantitis. *Dent Clin North Am* 2005;49:661-676.
 48. Berglundh T, Persson L, Klinge B. A systematic review of the incidence of biological and technical complications in implant dentistry reported in prospective longitudinal studies of at least 5 years. *J Clin Periodontol* 2002;29(Suppl.):197-212, 232-233.
 49. Roos-Jansäker AM, Lindahl C, Renvert H, Renvert S. Nine- to fourteen-year follow-up of implant treatment. Part II: Presence of peri-implant lesions. *J Clin Periodontol* 2006;33:290-295.
 50. LeGeros RZ, LeGeros JP, Kim Y, et al. Calcium phosphates in plasma-sprayed HA coatings. *Ceram Transact* 1995;48:173-189.
 51. Tranquilli PL, Merolli A, Palmacci O, Gabbi C, Cacchiolo A, Gonizzi G. Evaluation of different preparations of plasma-spray hydroxyapatite coating on titanium-alloy and duplex stainless-steel in rabbit. *J Mater Sci Mater Med* 1994;5:345-349.
 52. Johnson BW. HA-coated dental implants: Long-term consequences. *J Calif Dent Assoc* 1992;20:33-41.

Correspondence: Dr. Renée M. Stach, Biomet 3i, 4555 Riverside Dr., Palm Beach Gardens, FL 33418. Fax: 561/776-6852; e-mail: renee.stach@biomet.com.

Submitted August 21, 2009; accepted for publication November 20, 2009.